

Khomych N. N.,

professor,

Department of Surgical and Pediatric Dentistry,

Bukovinian State Medical University

Yavorskyi A. V.,

4 th year student of the faculty of dentistry

Department of Surgical and Pediatric Dentistry,

Bukovinian State Medical University

Kuzniak L. V.,

4 th year student of the faculty of dentistry

Department of Surgical and Pediatric Dentistry,

Bukovinian State Medical University

EFFECTIVENES OF DEXAMETHASONE IN MANAGEMENT OF PAIN AND INFLAMMATION AFTER CYSTECTOMY OF MAXILLARY RADICULAR CYSTS

Summary. The article presents the analysis of the clinical trial of 23 patients at 1, 3 and 7 days of the use of dexamethasone after cystectomy of radicular cysts of the upper jaw. Comparative evaluation of the efficacy of postoperative use of different doses of dexamethasone.

Key words: cystectomy, dexamethasone, pain, swelling.

Introduction. One of the most common surgical procedures performed by dental surgeons in an outpatient setting is cystectomy of maxillary radicular cysts [1, p. 69, 2, p. 72]. Surgical trauma during the procedure and adequacy of therapeutic interventions are the main factors that affect the postoperative rehabilitation process. Early postoperative complications occur in 6–15% of the patients, even if all the postoperative instructions by the surgeon were complied [3, p. 435]. Various medicamental therapy remedies are used to reduce postoperative pain and swelling and, to prevent the development of inflammatory complications [4, p. 25; 5, p. 11; 6, p. 49].

Corticosteroids are widely used in the treatment of diseases, disorders and conditions affecting the oral and maxillofacial area and the adjacent and associated structures. The diseases of the oral and maxillofacial

region may be either local or the manifestation of a systemic problem. Corticosteroids have their widest application in the management of acute and chronic conditions which have an allergic, immunologic, or inflammatory basis. Therefore, a group of corticosteroids which have predominantly a glucocorticoid activity and little or no mineralocorticoid action such as betamethasone, dexamethasone, triamcinolone, and prednisolone are used. Dexamethasone can be used locally, intramuscularly and intravenously [7, p. 226].

Local submucosal injection of dexamethasone is very common in the management of acute postoperative inflammation [7, p. 226; 8, p. 260; 9, p. 31]. So, the aim of this study was to improve the treatment of inflammatory complications by local submucosal injection of dexamethasone 4 or 8 mg in patients after cystectomy of maxillary radicular cysts and determination of the most effective dose.

Materials and methods. Twenty three patients who underwent cystectomy under local anesthesia were randomly selected for this study. The selected patients consisted of 13 females (56.5%) and 10 (43.5%) males with age ranging from 18 to 29 years. The patients were categorized into three groups:

– group № 1: Control (where no dexamethasone was used);

– group № 2: Dexamethasone of 4 mg at once after surgery was used;

– group № 3: Dexamethasone of 8 mg at once after surgery was used.

All patients were admitted to hospital in following a standard protocol. Each patient signed a consent form to participate in the study. Allergic reactions to medications were noted in three patients. All patients were admitted in the Department of Surgical Dentistry in satisfactory condition. Thirteen patients reported pain, recurrent soft tissue swelling, redness of the mucous membrane, slight purulent discharge, weakness and fever. Surgery was carried out after the acute inflammation symptoms were resolved.

Patients received antibiotics, eubiotics and local submucosal injection of dexamethasone. Anti-inflammatory drugs and pain medications were prescribed only as needed. Clinical examination of patients was performed after 1, 3, and 7 days postoperatively. Pain in the operated healing area was assessed by visual analogue scale. Visual analogue scale (VAS) is a 10 cm straight line. Starting point of the line indicates the absence of pain (0), followed by minimal, moderate, strong, very strong, and the maximum possible pain (10). Patients determined the level of pain point on this line.

The area of edema was determined by the «transparent reflections» as described by B. Postnikov [10,p.158]. This method consists of imposing a transparent film on the skin surface and using a dye (methylene blue or brilliant green) to contour edema. The film is then placed on a graph paper and area of swelling is calculated utilizing the following formula: $Se = \frac{1}{4}(Nc + Nhc/2 + Nqc/4)$, where Se: area of swelling, Nc: number of full cells, Nhc: number of halves, Nqc: number of quarters.

Results and discussion. Using of dexamethasone to prevent postoperative pain and swelling after the cystectomy showed positive outcome during postoperative period, with less pronounced clinical symptoms of pain and swelling and accelerated pace of their fading. The most pronounced affects were seen on 3rd day postoperatively, as evidenced by VAS index; with patients in both experimental groups noticing lower pain feelings than the control group (Table 1, Figure 1).

Intensive reactive edema was observed in all the groups on the 1st day after surgery. However; the control group had significantly increased edema on the third postoperative day as compared to the experimental groups who had only slight edema. (Table 2, Figure 2).

Table 1

Assessment of pain by visual analogue scale

Post-Operative Day	Control Group (n= 8)	Experimental Group 1 (n=8)		Experimental Group 2 (n=7)	
	M±m	M±m	P1	M±m	P1
1st	5.6±0.18	4.5±0,16	<0.05	4.2±0.16	<0.05
3rd	3.7±0.15	2.5±0,14	<0.05	2.3±0.14	<0.05
7th	0.4±0.14	0	>0.05	0	>0.05

Table 2

Comparison of postoperative swelling area (m²) between control and experimental groups

Post-Operative Day	Control Group (n= 8)	Experimental Group 1 (n=8)		Experimental Group 2 (n=7)	
	M±m	M±m	P1	M±m	P1
1st	84.6±0.13	68.05±0.15	<0.05	65.4±0.13	<0.05
3rd	47.6±0.11	36.85±0.09	<0.05	32.5±0.1	<0.05
7th	23.3±0.07	14.5±0.09	<0.05	12.05±0.09	<0.05

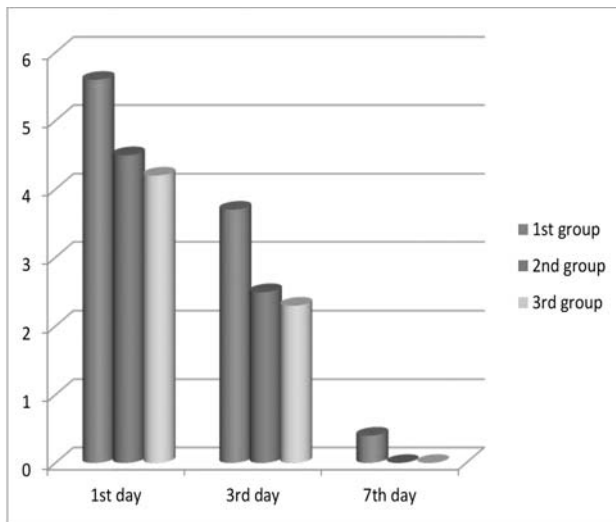


Figure 1. Assessment of pain by visual analogue scale

Conclusions.

1. Dexamethasone is used, either singly or in combination with other drugs, for the treatment of various diseases affecting oral and maxillofacial area.
2. It is also frequently used to minimize expected post-operative morbidities such as pain and edema after oral and maxillofacial surgeries.
3. Local submucosal injection of dexamethasone reduced postoperative pain and swelling after cystectomy of maxillary radicular cysts.
4. Both of doses of dexamethasone were equally effective.

References:

1. Malanchuk V.O. Method of surgical treatment of lower wisdom teeth / V.O. Malanchuk // Journal of Dentistry. – 2006. – Vol. 2. – P. 69–71.
2. Solovyov M.M. Treatment of odontogenic cysts / M.M. Solovyov // St. Petersburg, Spec-Lithuania. – 2004. – p. 127.
3. Timofeev A.A. Guide to maxilla-facial surgery and surgical dentistry / A.A. Timofeev // Ruta, Kyiv. – 2000. – P. 1022.
4. Deo S.P. Effect of submucosal injection of dexamethasone on post-operative sequelae / S.P. Deo, P. Shetty // Journal of Nepal Medical Association. – 2011. – Vol. 51 (182). – P. 25–30.
5. Effects of co-administered dexamethasone and diclofenac potassium on pain, swelling and trismus following third molar surgery / B.O. Bamgbose, J.A. Akinwande, W.L. Adeyemo, A.L. Ladeinde, G.T. Arotiba, M.O. Ogunlewe. // Head & Face Medicine – 2005. – Vol. 1. – P. 11.
6. Kuznetsov O.F. Treatment of patients with hastrroduodenal diseases / O.F. Kuznetsov,

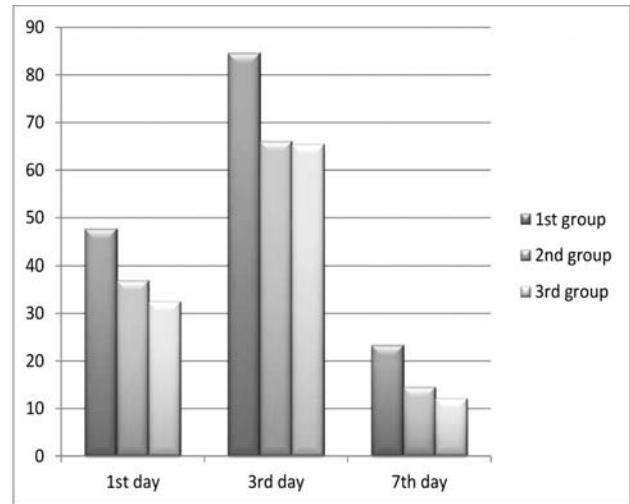


Figure 2. Comparison of postoperative swelling area (m²) between control and experimental groups

R.M. Filimonov, N.M. Fur, E.M. Styazhkyna // Physiotherapy, Rehabilitation and Balneology – 2006. – Vol. 6. – P. 49–52.

7. Markovoric A. Effectiveness of dexamethasone and low-power laser in minimizing oedema / A. Markovoric, L.J. Todovoric // Int. J. Oral Maxillofac. Surg. – 2007. – Vol. 36(3). – P. 226–229.
8. Vegas-Bustamante E. Efficacy of methylprednisolone injected into the masseter muscle following the surgical extraction of impacted lower third molars // International journal of oral and maxillofacial surgery. – 2008. – Vol. 37. – P. 260–263.
9. Kaur S. To study the efficacy of dexamethasone injected into the masseter muscle in controlling post operative sequelae / S. Kaur, T.P. Ahluwalia and G.B. Sandeep // Farid University Dental Journal. – 2013. – Vol. 4. – P. 31–37.
10. Cherenko M.P. General surgery / M.P. Cherenko // Health, Kyiv. – 1999. – p. 215.

**Хомич Н. М., Яворський А. В., Кузник Л. В.
Ефективність використання дексаметазону для попередження запальних ускладнень після операції цистектомії у фронтальній ділянці верхньої щелепи**

Анотація. У статті представлено аналіз результатів клінічного дослідження проведеного у 23 хворих на 1, 3 та 7-у добу застосування дексаметазону після операції цистектомії з приводу радикулярних кіст зубів фронтального відділу верхньої щелепи. Проведена порівняльна оцінка ефективності післяопераційного застосування різних доз дексаметазону.

Ключові слова: цистектомія, дексаметазон, біль, набряк.

Хомич Н. Н., Яворский А. В., Кузник Л. В.
Эффективность использования дексаметазона для предупреждения воспалительных осложнений после операции цистэктомии во фронтальном участке верхней челюсти

Аннотация. В статье представлен анализ результатов клинического исследования, проведенного у 23 больных на 1, 3 и 7-е сутки

применения дексаметазона после операции цистэктомии по поводу радикулярных кист зубов фронтального отдела верхней челюсти. Проведена сравнительная оценка эффективности послеоперационного применения различных доз дексаметазона.

Ключевые слова: цистэктомия, дексаметазон, боль, отёк.